

Cases from the STI Clinic

STI Update

November 4 2021

Panelists: Terry Marcotte, Yvonne Piper, Meena Ramchandani

Moderator: Oliver Bacon

Objectives

- Proctitis: Diagnostic approach depending on your resources; empiric therapy for likely causes; special cases
- Neuro/ocular/oto-syphilis: When to suspect; diagnostic approach; getting specialist help; therapeutic options; follow-up
- PrEP: same day start in someone with risk of recent infection
- Syphilis cases: Quickies with the experts

Case 1

- 27, MSM, HIV(-) on PrEP
- GC/CT/HIV/RPR (-) at last quarterly visit 1 month ago
- 1 week of worsening rectal pain, with some blood on toilet paper, “mucous” on stool
- Oral sex: gives and receives
- Anal sex: tops and bottoms
- “I think I have a hemorrhoid”
- On exam he has a firm skin tag in the left anterolateral perianal region

Audience Poll: What diagnostic procedures are available to you?

1. 3-site GC/CT NAAT testing
2. Gram stain of rectal discharge
3. Rectal PCR for lymphogranuloma venereum (LGV), HSV
4. (1) and (2)
5. (1) (2) and (3)

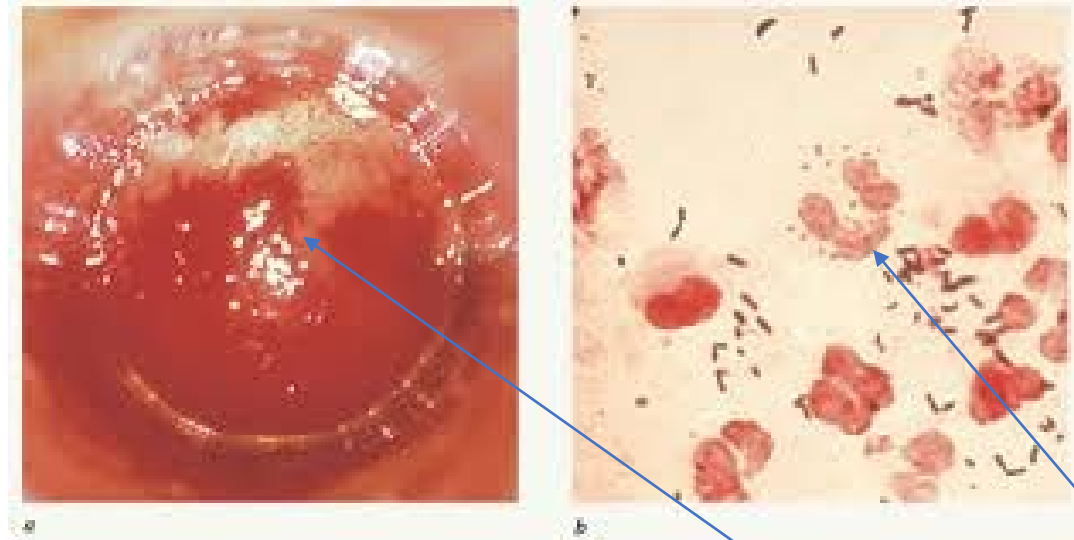
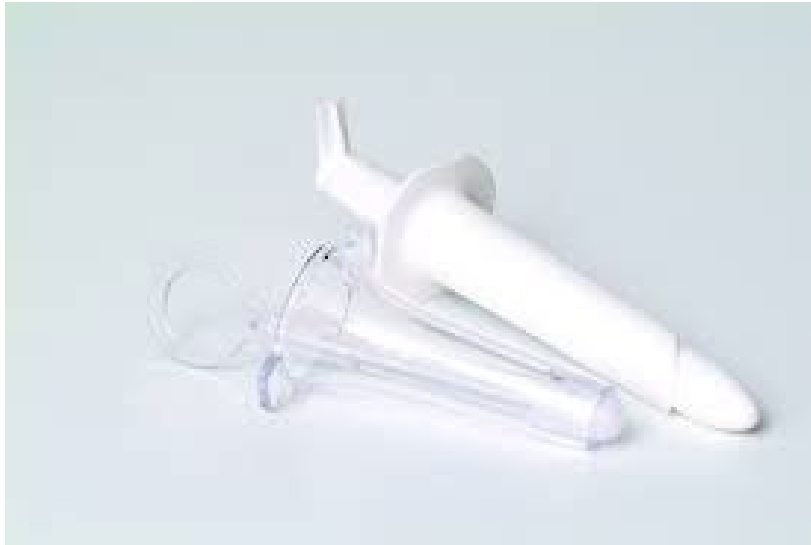Audience Poll: What would you treat him with?

1. Ceftriaxone 250 mg IM x 1 + azithromycin 1 g PO x 1
2. Ceftriaxone 500 mg IM x 1 + doxycycline 100 mg PO BID x 7 days
3. Ceftriaxone 500 mg IM x 1 + doxycycline 100 mg PO BID x 21 days
4. (3) + acyclovir 400 mg TID x 10 days

Panel: What would you treat him with?

1. Ceftriaxone 250 mg IM x 1 + azithromycin 1 g PO x 1
2. Ceftriaxone 500 mg IM x 1 + doxycycline 100 mg PO BID x 7 days
3. Ceftriaxone 500 mg IM x 1 + doxycycline 100 mg PO BID x 21 days
4. (3) + acyclovir 400 mg TID x 10 days

Proctitis



Characterized by anal pain/discomfort, purulent discharge (sometimes bloody), tenesmus

≥ 1 PMN on Gram stain

Friable mucosae w discharge

Proctitis (sexually transmitted): microbiology

Most common causes

- *Chlamydia trachomatis*
 - Lymphogranuloma Venerium (LGV)
- *Neisseria gonorrhoea*
- *Herpes Simplex*
- Rarely *Treponema pallidum*
- ?????? *Mycoplasma genitalium* ???
 - Association but unclear if causative

Lymphogranuloma venereum

- ***Chlamydia trachomatis***
 - Serovars L1, L2, L3
 - Compared to other serotypes of CT, more invasive and virulent, tending to result in systemic disease
 - Organism travels through lymphatics to multiply within macrophages in regional lymph nodes (c/w non LGV serovars, which infect epithelial cells)
- Transmission – primarily sexual
- Endemic in some regions, in 2000's outbreaks reported in MSM in Europe, primarily proctitis
- Reservoir not defined, ? presence of asymptomatic carrier state
- Primary clinical presentation described in SF is proctitis/proctocolitis
 - Can lead to chronic colorectal fistulas, strictures, reactive arthropathy
- Penile/urethral infections occur: fleeting chancre followed by tender unilateral inguinal bubo, may be accompanied by lymphangitis along penile shaft (bubonulus)

Panel: Proctitis workup and empiric treatment

- What aspects of the patient history prompt you to work them up for proctitis?
- Given the resources at your clinic, what diagnostic procedures do you perform?
- If you don't see WBC on rectal Gram stain, do you treat for proctitis anyway?
- When do you send LGV PCR?
- What would be your approach to diagnosis and treatment if all you had was history, exam, and GC/CT NAATs and anoscopy?

Proctitis: diagnosis and treatment

Testing: anoscopy with rectal swabs (blind swabs if anoscopy not tolerated)

- Gram stain of rectal swab if available
- NAAT for *Neisseria gonorrhoea*, *Chlamydia trachomatis*
- HSV PCR if available
- LGV PCR if available

Recommended empiric regimens

- Ceftriaxone 500 mg IM x 1 + doxycycline 100mg BID x 7d
- Consider empiric acyclovir if ulcers, bloody painful discharge and HSV PCR pending

LGV : Clinical Management

- Suspect when patient has rectal pain, +/- tenesmus, mucopurulent discharge +/- blood
- Order rectal GC, CT NAATs, HSV PCR. If rectal CT (-), it's not LGV
- Abdominal CT if concern for abscess, perforation
- In San Francisco, LGV PCR available via SFDPH to confirm, but not timely to guide treatment decisions – call STD for assistance.
- Treat empirically, pending lab confirmation
- Doxycycline 100mg BID x 21d or until sx's completely resolve
 - Azithromycin 1 g q7d x 3 weeks may be an alternative, but data are sparse
 - Treat asymptomatic contacts in last 60d with doxy 100mg BID x 7d (or azithromycin 1 g)

Case 1: diagnosis

- Rectal CT NAAT (+)
- Rectal LGV PCR (+)
- At follow up 28 days later he is asymptomatic and the skin tag (lymphorrhoid) has resolved.

NEW! Chlamydia treatment guidelines: urogenital, rectal, pharyngeal

Non-pregnant persons:

Recommended regimen:

- Doxycycline 100 mg PO BID x 7 days (moved up)

Alternatives:

- Azithromycin 1 g PO x 1 (moved down)
- Extended-release doxycycline 200 mg PO daily x 7 days
- Levofloxacin 500 mg PO daily x 7 days

Pregnancy not ruled out, or not on highly effective birth control:

Recommended regimen: Azithromycin 1 g PO x 1

Alternative: Amoxicillin 500 mg PO TID x 7 days

Why the change from azithro to doxy?

- Meta-analyses of urogenital and rectal CT treatment favoring doxy over azithro in symptomatic penile urethral infections, rectal infections; equivalence in cervical infections.
- RCTs of doxy vs azithro for rectal CT strongly favoring doxy
- Rectal chlamydia may be more prevalent than previously appreciated, including in cisgender women, and in persons who do not report receptive anal sex; may be an asymptomatic reservoir of infection
- Antibiotic stewardship issues with azithromycin

Azithromycin 1g vs Doxycycline 100mg BID x 7d for Urogenital Chlamydia

Kong et al: metaanalysis of 23 RCTs (CID 2014:59, 15 July)

- Pooled efficacy in favor of doxy (all sexes): 1.5%-2.6%
- Pooled efficacy in favor of doxy (symptomatic male urethral): 5.5%-7.5%

Paez-Canro et al: Metaanalysis of 14 RCTs (Cochrane Database, 2019)

- Risk of microbiological failure in men higher with azithro vs doxy: RR 2.45 (95%CI 1.36-4.41), no difference in adverse events.
- Risk of microbiological failure in women uncertain between 2 drugs: RR 1.71 (95%CI 0.48-6.16), no studies of adverse events.

Azithromycin 1g vs Doxycycline 100mg BID x 7d for Rectal Chlamydia

The efficacy of azithromycin and doxycycline for the treatment of rectal chlamydia infection: a systematic review and meta-analysis

Fabian Yuh Shiong Kong^{1*}, Sepehr N. Tabrizi^{2,3}, Christopher Kincaid Fairley^{4,5}, Lenka A. Vodstrcil^{1,2,5},
Wilhelmina M. Huston⁶, Marcus Chen⁵, Catriona Bradshaw⁵ and Jane S. Hocking¹

- Metaanalysis of 8 observational studies of azithro 1g and doxycycline 100mg x 7d for rectal Chlamydia in men and women
- 3 azithro only, 5 azithro vs doxy
- Pooled efficacy for Azithro: 82.9% (95%CI 76.0-89.9%)
- Pooled efficacy for doxy: 99.6% (95%CI 98.6%-100%)
- Pooled efficacy difference: 19.9% (95%CI 11.4%-28.3%) in favor of doxy

J Antimicrob Chemother 2015; **70**: 1290–1297

doi:10.1093/jac/dku574 Advance Access publication 29 January 2015

Additional observational studies show improved efficacy of Doxy vs azithro for rectal Chlamydia in women at re-test

- Dukers Muijers et al, CID, 2019: 96% vs 79% (p<.001) for rectal CT in women; no difference for vaginal CT

Prevalence of rectal chlamydia in women 2%-77% (median 8.7%) in STD clinics, mostly asymptomatic, and many in women NOT reporting receptive anal sex (P Chan et al, Inf Dis in Obs Gyn, 2016)

5 studies compared Doxy 100mg BID x7d vs Azithro 1g:

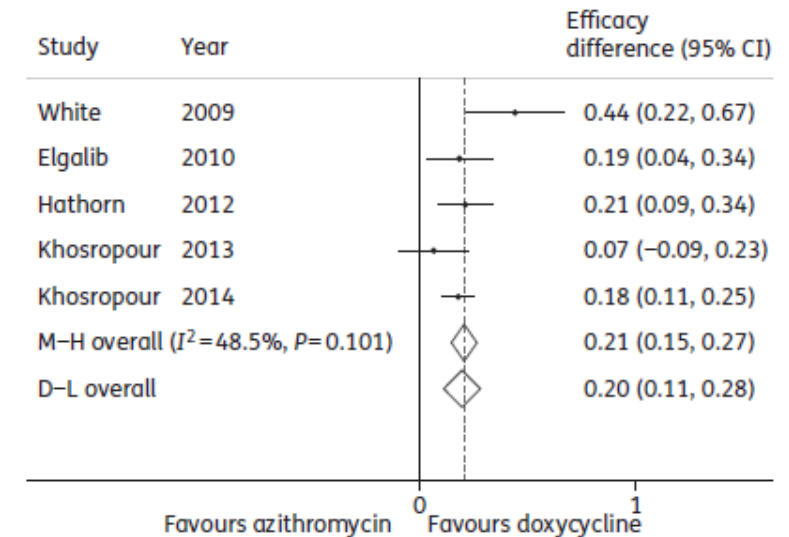


Figure 4. Efficacy difference between 7 days of doxycycline versus single-dose azithromycin for the treatment of rectal chlamydia infections. M-H, Mantel-Haenszel (fixed) methods.



A Randomized Trial of Azithromycin vs. Doxycycline for the Treatment of Rectal Chlamydia in Men who Have Sex with Men

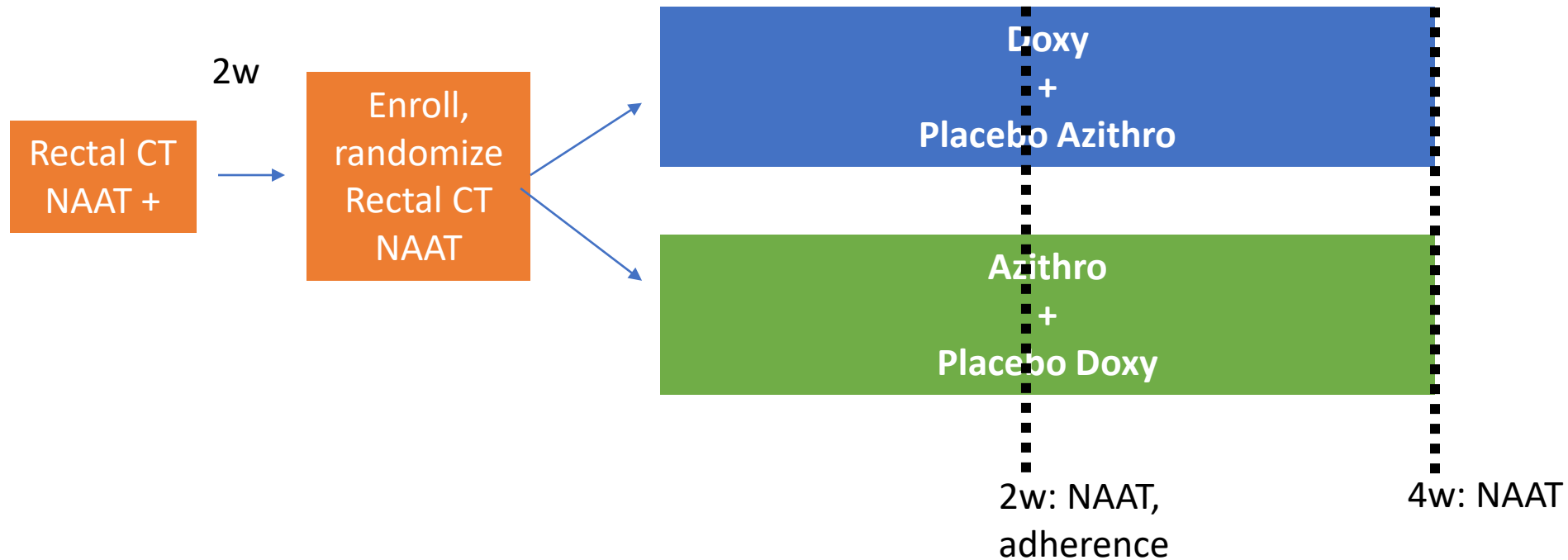
(DMID Protocol 17-0092)

Julie Dombrowski, Michael R. Wierzbicki, Lori Newman, Jonathan Powell, Ashley Miller, Dwyn Dithmer, Olusegun Soge, Kenneth H. Mayer

2020 STD Prevention Conference



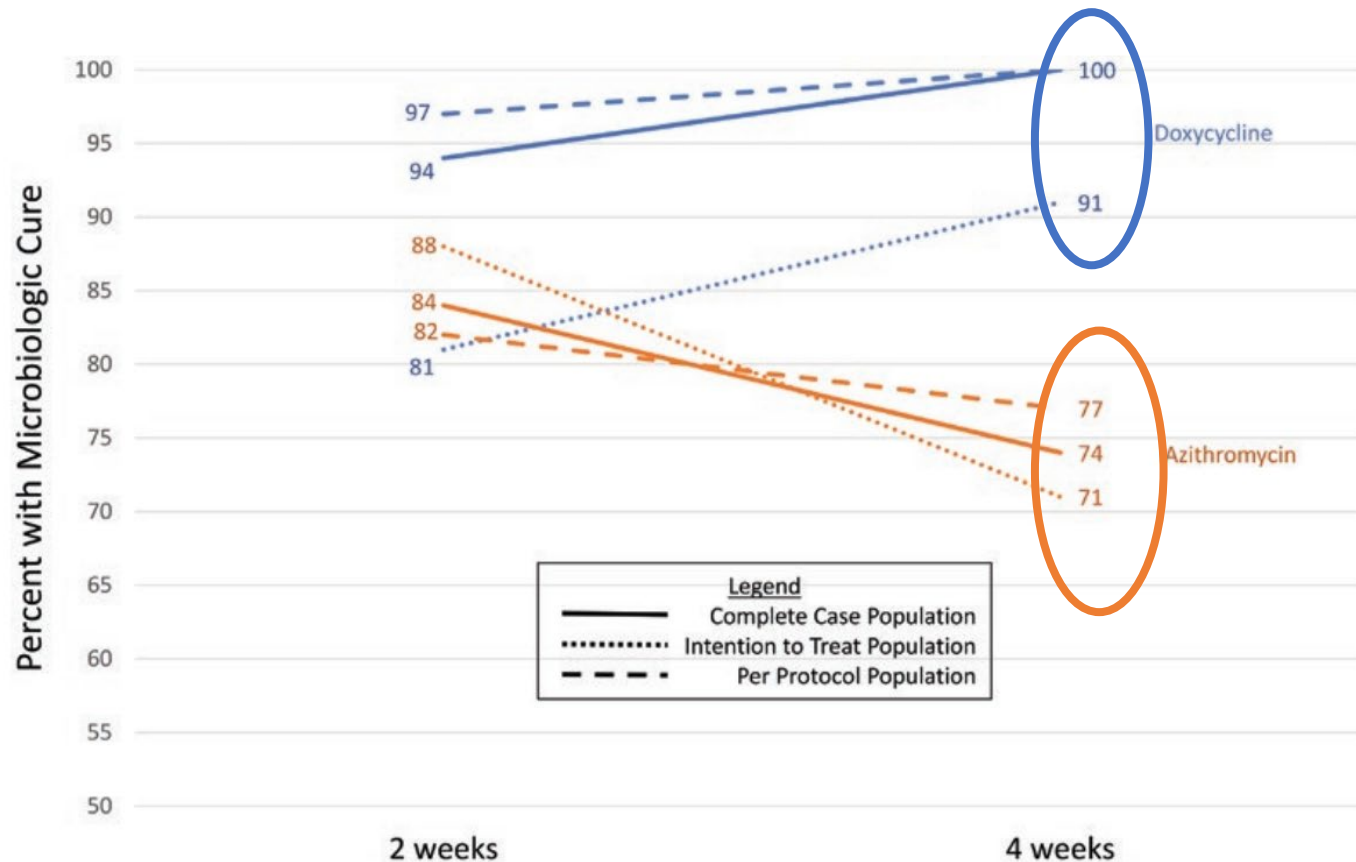
design



- Complete Case (CC): CT+ at enrollment, completed NAATs at visit of analysis (2 or 4 weeks)
- ITT: all enrolled participants
- PP: CC + adherent and abstinent from ncRAI during study
- Interim analysis at midpoint: stopped by DSMB for significant difference in efficacy after 177 of planned 274 enrolled by X^2 test of proportion with microbiologic cure in doxy vs. azithro arms

Doxycycline Versus Azithromycin for the Treatment of Rectal Chlamydia in Men Who Have Sex With Men: A Randomized Controlled Trial

Julia C. Dombrowski,^{1,2} Michael R. Wierzbicki,³ Lori M. Newman,⁴ Jonathan A. Powell,³ Ashley Miller,⁵ Dwyn Dithmer,² Olusegun O. Soge,⁶ and Kenneth H. Mayer^{7,8}



Outcome: microbiologic cure at 4W
% efficacy increase w Doxy over AZM:

CC: 26% (95%CI 16-36%) p<.001
 ITT: 20% (95%CI 91%-71%) p<.001
 PP: 23% (95%CI 11%-35%) p<.001

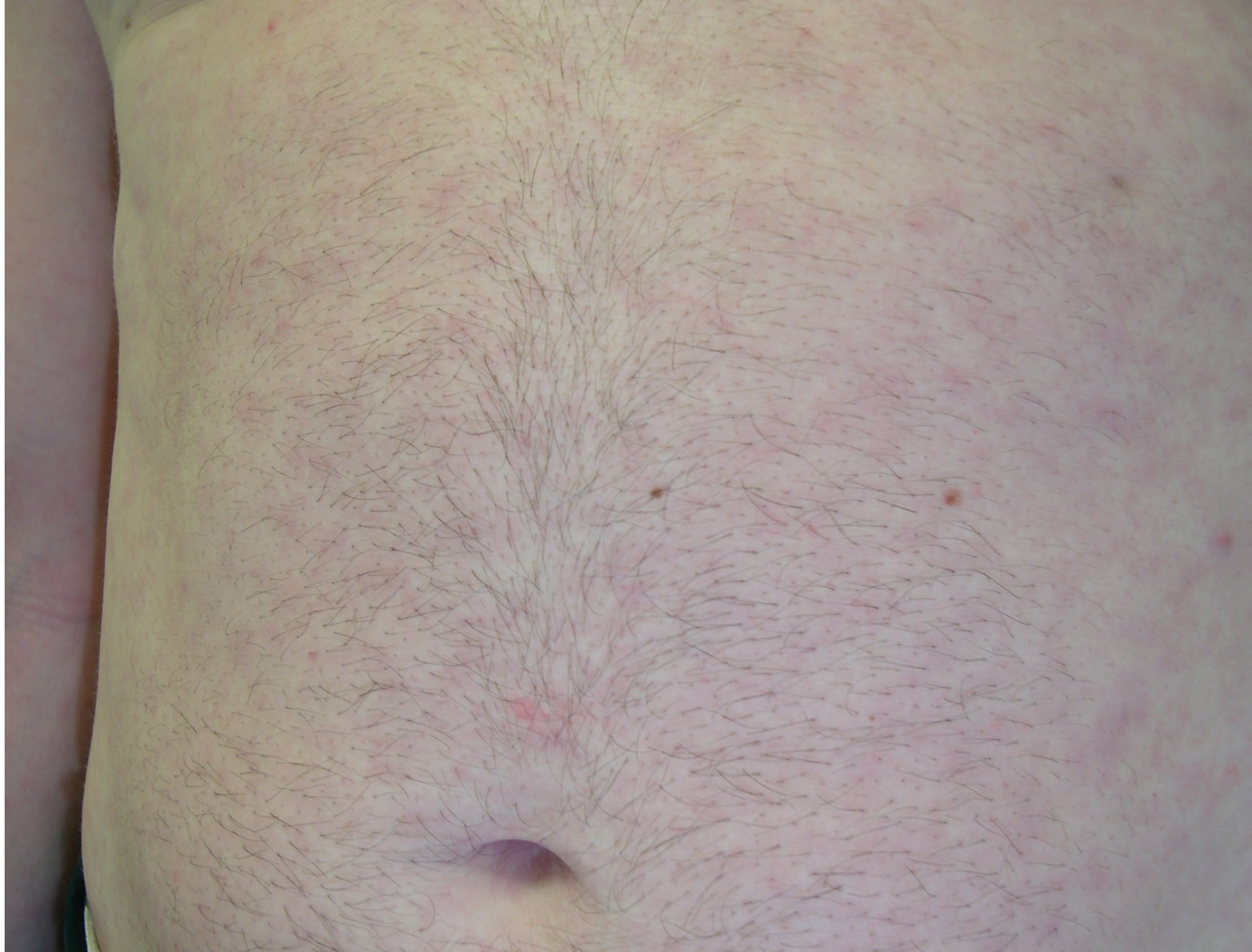
Other interesting findings:

- 20% cleared infection in 14d between screening and enrollment
- Doxy “adherence” = 10 doses (1st dose DOT) in 10 days: 100% cure in adherent group
- 8 cases of LGV: 4/4 cured in doxy group, 3/4 cured in AZM.

See also: “Azithromycin or Doxycycline for Asymptomatic Rectal *Chlamydia Trachomatis*,” Lau et al. NEJM 2021;384:2418-27: adjusted risk difference 19.9% (95%CI 14.6-25.3) favoring Doxy

Case 2

- 42-year-old cisgender male patient, referred by his male partner, whom you just treated for latent syphilis of unknown duration. Patient is in the waiting room.
- Diagnosed with HIV 5 years ago, never took ART due to fear of medical system. CD4 count, viral load unknown. Never had pneumonia, meningitis, or thrush.
- Patient has a nonpruritic maculopapular rash on his torso and arms. He notes worsening blurry vision over the last three weeks and has to be escorted to the exam room. He can shapes moving when you wave your hands in front of his face.
- The remainder of his cranial nerve exam is normal



Audience poll: What would you do?

1. Order RPR
2. Perform lumbar puncture to obtain CSF for cell count, VDRL +/- FTA-abs
3. Send to ED for immediate ophthalmologic exam/consult
4. (1) and (3)
5. (1) (2) and (3) and give 2.4 MU benzathine penicillin before he goes to the ED

Panel: Patient is a contact to syphilis, is living with HIV, has a suspicious rash, and has recent decrease in visual acuity

- How would you manage this patient?
 - What symptoms or findings related to the eye (in general) make you include ocular syphilis in your differential diagnosis?
 - In this case, we don't have a reactive RPR (yet). Do you have an alternative explanation for his rash? Can you obtain a stat RPR while the patient waits? Would you trust a nonreactive result?
 - If you couldn't get a stat RPR, or it was nonreactive, would you proceed with workup and treatment anyway?

Case, continued

- Stat RPR is reactive. Patient reluctantly agrees to go to emergency department
- CSF: 80 WBC, Protein 100, VDRL 1:16*; serum T.pallidum EIA is reactive; starts penicillin G 4 MU IV every 4 hours in the ED and is admitted.
- Dilated slit-lamp exam shows bilateral chorioretinitis with vitritis. RPR is 1:1024.
- CD4 count 1 c/mm³; HIV RNA 450,000 c/mL
- On the morning of day 5, he can read the ingredient list on his breakfast orange juice container. He agrees to start antiretroviral therapy but says he can't stay in the hospital any longer and wants go stay with his partner in their RV, which is parked in Candlestick Park. "Can't you give me a shot or pills?"

Neuro/ocular/oto syphilis treatment

- Recommended regimen:
 - Aqueous Crystalline Penicillin G 18-24 mu IV daily administered as 3-4 million units IV q 4 h for 10 -14 days
- Alternative regimen (if compliance can be assured):
 - Procaine Penicillin G 2.4 mu IM daily plus Probenecid 500 mg PO q d, both for 10-14 d
- ***Consider: BIC 2.4 million units IM once per week up to 3 weeks after completion of 10-14 day course for late syphilis***

Ocular Syphilis can affect any part of the globe

Manifestations:

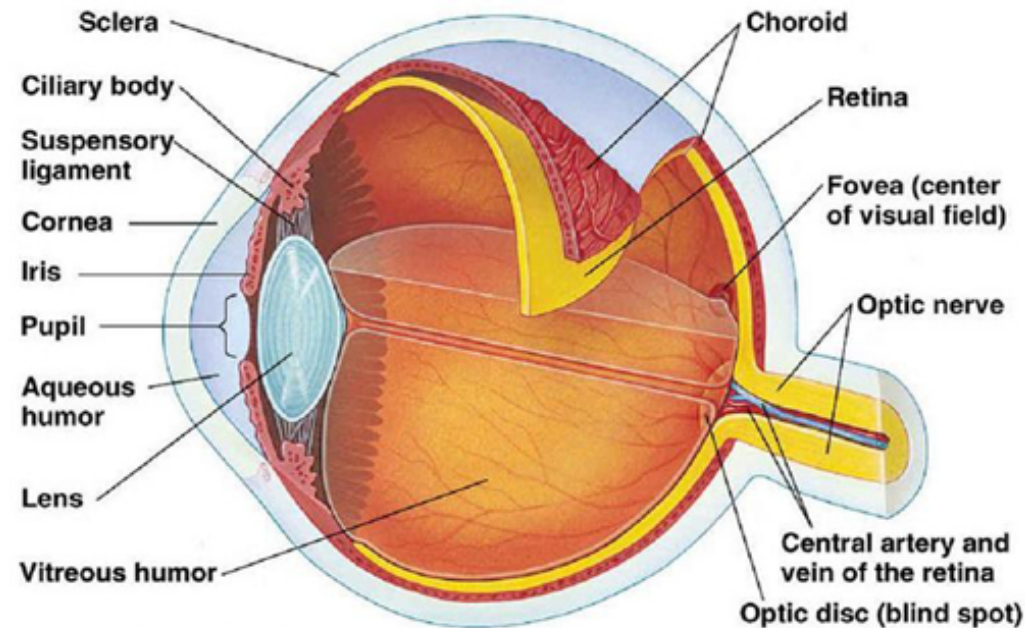
- Conjunctivitis, scleritis, and episcleritis
- **Uveitis**: anterior and/or posterior
- Elevated intraocular pressure
- **Chorioretinitis**, retinitis
- Vasculitis

Symptoms:

- Redness
- Eye pain
- Floaters
- Flashing lights
- Visual acuity loss
- Blindness

Diagnosis:

- Ophthalmologic exam
- Serologies: RPR, VDRL, treponemal tests
- Lumbar puncture



Congenital syphilis: This group embraces notably patients with interstitial keratitis.
Secondary and late secondary syphilis: This group embraces patients with uveitis and chorioretinitis.

AJO 1930; 13:285-294

Slide courtesy of Sarah Lewis, MD

Ocular Manifestations of Syphilis: **Up to 50% Bilateral**

Lids

- Chancre
- Gumma
- Tarsitis
- Ulcerative blepharitis

Cornea

- Interstitial keratitis
- Ulcers
- Deep, punctate keratitis
- Keratitis profunda
- Keratitis punctate profunda
- Keratitis linearis migrans
- Gumma

Retina and Vitreous

- Chorioretinitis-pseudoretinitis, pigmentosa, salt and pepper fundus
- Perivasculitis
- Central retinal artery/vein occlusion
- Cystoid macular edema
- Vitritis

Conjunctiva

- Chancre
- Papular syphilides
- Gumma

Sclera

- Episcleritis
- Anterior nodular scleritis
- Gumma

Optic Nerve

- Neuritis
- Perineuritis
- Neuroretinitis
- Gumma

Orbit

- Periostitis
- Gumma

Iris and Ciliary Body

- Roseolae
- Papules
- Gumma
- Iritis
- Anterior Uveitis

Motility Dysfunction

- Oculomotor, abducens, troclear paresis – associated with basilar meningitis
- Periodic alternating nystagmus

Anterior Chamber Hypopyon

Lens

- Capsular rupture and necrotizing cortical inflammation (congenital syphilis)
- Dislocation

Pupils

Light-near dissociation

Ocular Syphilis — Eight Jurisdictions, United States, 2014–2015

MMWR / November 4, 2016 / Vol. 65 / No. 43

TABLE 2. Demographic characteristics of patients with suspected ocular syphilis — eight jurisdictions, United States, 2014–2015

Characteristic	No.	(%)
Total	388	(100.0)
Male	362	(93.3)
Known MSM (among 362 males)	249	(68.8)
Race		
White	217	(55.9)
Black	81	(20.9)
Hispanic	48	(12.4)
Asian	13	(3.4)
Native Hawaiian/Pacific Islander	1	(0.3)
Other/Unknown	28	(7.2)
HIV-positive	198	(51.0)

Abbreviations: HIV = human immunodeficiency virus; MSM = men who have sex with men.

TABLE 3. Clinical characteristics, laboratory results and diagnoses for syphilis and suspected ocular syphilis — eight jurisdictions, United States, 2014–2015

Characteristic	No.	(%)
Total	388	(100.0)
Stage of syphilis		
Primary	8	(2.1)
Secondary	101	(26.0)
Early latent	79	(20.4)
Late or latent of unknown duration	193	(49.7)
Unknown	7	(1.8)
Additional symptoms of neurosyphilis	87	(22.4)
Reported ocular symptoms (among 326 with symptoms)		
Blurry vision	210	(64.4)
Vision loss	107	(32.8)
Eye pain or red eye	46	(14.1)
Eye exam	158	(40.7)
Diagnosis (among 158 with documented eye exam)*		
Uveitis	72	(45.6)
Retinitis	20	(12.7)
Optic neuritis	18	(11.4)
Retinal detachment	6	(3.8)

What are the characteristics of ocular syphilis among HIV co-infected persons?

Characteristics	Total (n= 101)	CD4 count <200 cells/mm ³ (n= 17)	p Value <0.1‡
Median age (range) (years)	38.5 (23–62)	39.5 (23–50)	
Male (%)	96.9	100	
Median CD4 (range) (cells/mm ³)	348 (4–1435)	61 (4–181)	
CD4>200 (%)	74	NA	
200>CD4>50 (%)	7	71	
CD4<50 (%)	10	29	
Median HIV-1 RNA (range) (copies/ml)	1800 (30 copies–1.9 million copies)	1.9 million	
Ocular findings	n=86		
Bilateral (%)	63	56	
Anterior uveitis (%)	17	0	0.16
Posterior uveitis (%)	54	93	0.002
Panuveitis (%)	20	0	0.055
Optic neuritis (%)	20	14	
Clinical manifestations	n=54		
Only visual symptoms (%)	39	60	
Rash of secondary syphilis (%)	55	50	
CSF findings	n=64		
WBC elevated* (%)	74	90	
Total protein elevated† (%)	75	78	
VDRL positive (%)	57	58	

- Limited objective data in HIV-co-infected persons with syphilis
- Unclear if HIV infection increases the risk for ocular manifestations
- Association between posterior uveitis and lower CD4 cell counts

Diagnostic Criteria

- Ocular signs and symptoms in a person who has syphilis
- Most will have positive serological tests
 - In patients with **late** ocular syphilis, up to 30% may have a nonreactive serum RPR/VDRL but will have a reactive serum treponemal test
- Up to 70% of patients with ocular syphilis will have CSF abnormalities
- CSF can be normal

Syphilis Treatment Updates: 2021 CDC STI Guidelines

- **No new data to warrant a change in treatment recommendations**
- Follow-up to document serologic response or failure after appropriate therapy
 - 12 months after treatment for early syphilis (1ary, 2ary, early latent)
 - 24 months after treatment for late latent, latent of unknown duration, or late syphilis in case of syphilis of unknown duration or late syphilis
- Neurosyphilis: repeated CSF examinations are unnecessary for persons without HIV infection or persons with HIV infection who are on ART, and who exhibit serologic and clinical responses after treatment
- Ocular/otosyphilis: Need immediate ophthalmologic/audiometric exams; LP not absolutely necessary in absence of any other neurologic findings.

Optimal management approach

- Syphilis of the eye can progress very rapidly and cause blindness
- Patients must be evaluated immediately by an ophthalmologist
 - **Do NOT delay antibiotics while waiting for a lumbar puncture to be done**
 - **Recovery of vision correlated w shorter time from onset to treatment**
- Treat as neurosyphilis even if CSF normal
- **Report** cases of ocular syphilis to the local health department within 1 business day.

Role of adjunctive corticosteroid therapy

- **No clear evidence for benefit or harm**
- **Topical corticosteroids** have been used as treatment adjuncts for syphilitic interstitial keratitis, anterior uveitis and iridocyclitis
- **Oral and intravenous corticosteroids** have been used as treatment adjuncts for posterior uveitis, scleritis, and optic neuritis
- **Intravitreal injections** of triamcinolone may be harmful
- Case report of intravitreal ceftazidime (2.25 mg/0.1mL) in a PCN allergic pt

Panel: What would you do next?

1. Obtain 5150, psychiatric hold, continue IV penicillin, hope the hold lasts through day 10 of his treatment course.
2. Offer ceftriaxone 2 g IM once daily to complete 14 days of therapy as an outpatient if he will agree to come to infusion center daily.
3. Offer procaine penicillin G 2.5 MU IM once daily plus 500mg probenecid PO QID, both for 10-14 days as an outpatient if he will agree to come to the infusion center daily
4. Offer doxycycline 100mg PO BID x 28 days with every-other-day follow-up in HIV clinic

Case 3

- 27 y.o. transgender female, who uses she/her pronouns, comes to clinic with 2 days of dysuria. She noticed yellow urethral discharge this morning.
- Her medical/surgical history is unremarkable, and she has no kidney or bone disease. She takes estrogen and spironolactone. She has no drug allergies.
- She has insertive and receptive anal sex and performs and receives fellatio with cisgender men. She has had 5 partners in the last 3 months and used condoms for anal sex with 2 of them. None are living with HIV, as far as she knows. Her most recent sexual encounter included condomless receptive and insertive anal sex 2 nights ago.
- She reports HIV(-) in January 2021. One of her recent male partners offered her some of the Descovy[®] he is taking for PrEP. He takes it only around the time he has sex. She is interested in knowing more.

Panel:

- Do you define PrEP “eligibility” in line with the CDC or use your own criteria when deciding to offer PrEP (and tell us what they are please!)
- This patient is interested in learning more about PrEP, but do you ever have to sell the idea to patients, and how do you do that?
- Would you give her tenofovir alafenamide/emtricitabine (Descovy®) or tenofovir disoproxil fumarate/emtricitabine (either Truvada® or generic TDF/FTC)? Daily or 2-1-1? How would you choose between the two pills? Between the two dosing strategies?

Audience Poll:

After your extremely effective and patient centered counseling, she wants to start Daily PrEP with TDF/FTC! Yay! Also, you can do a urethral Gram stain! Yay! It shows GNIDs! Boo!

In addition to giving her ceftriaxone 500mg IM x 1 plus doxycycline 100mg PO BID x 7 days, what HIV testing would you order:

1. Rapid fingerstick HIV 1/2 EIA
2. Lab-based HIV p24 Ag/Ab with reflex to GEENIUS HIV 1/2 differentiation antibody
3. Rapid fingerstick EIA *and* HIV RNA (viral load)

Panel:

What HIV testing would you order (and why....):

1. Rapid fingerstick HIV 1/2 EIA
2. Lab-based HIV p24 Ag/Ab with reflex to GEENIUS HIV 1/2 differentiation antibody
3. Rapid fingerstick EIA *and* HIV RNA (viral load)

Panel:

What would you prescribe her for PrEP (and factor in the type of HIV testing you would have done if you would like)?

1. TDF/FTC 1 PO daily #30, 2 refills, start today
2. TDF/FTC 1 PO daily #30, 2 refills, start after HIV p24 Ag/Ab or HIV RNA return negative
3. Dolutegravir (Tivicay[®]) 50 mg po daily x 28 days #30, 0 refills and TDF/FTC 1 po daily #30, 2 refills, start both medications today
4. Something else?

Some syphilis serology cases

Fasten your seatbelts, it's going to be a bumpy evening.....



Bonus points if you know the movie, and feel free to type it into the chat

Case 4

- 32 y.o. cisgender female, HIV(-). Pelvic discomfort, “warts” x 1 week
- LMP 2 months ago. uHCG(+) today
- Has had 2 male partners in last 6 months: Partner A (sex started 1 month ago), and Partner B (sex ended 4 months ago).
- No history of syphilis
- RPR 1:128, TPPA reactive
- On exam: flat, moist rubbery nodules at introitus
- No medication allergies
- HATES needles

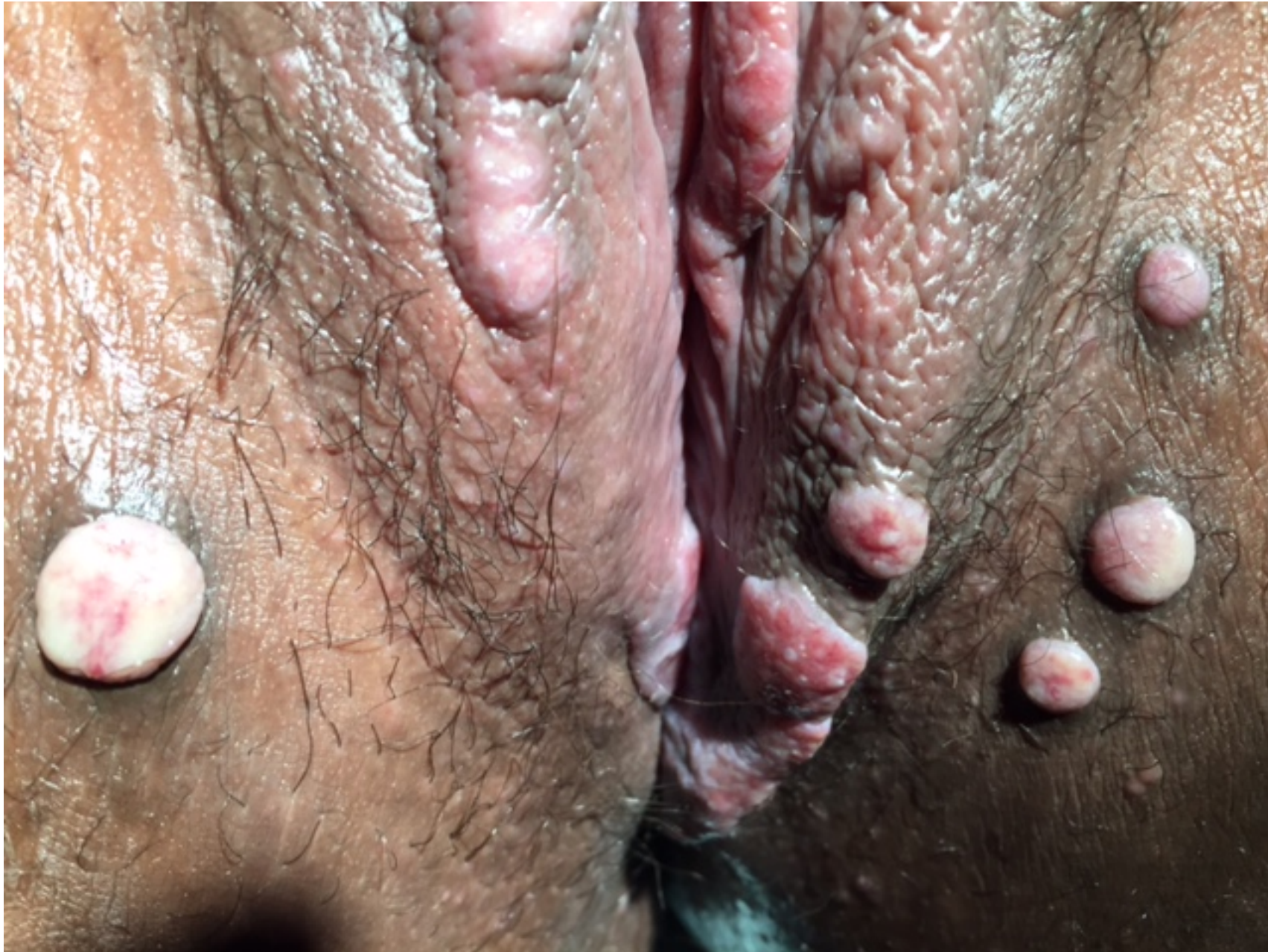

Image Courtesy of Joe Engelman, MD

Case 4 Panel: what would you treat her with?

1. Liquid nitrogen
2. Bicillin 2.4MU IM once weekly x 3 weeks
3. Bicillin 2.4MU IM once
4. Doxycycline 100mg PO BID x 14 days
5. Doxycycline 100mg PO BID x 28 days

Case 4: what about Partner A?

- 28, cis-gender man, HIV (-)
- Treated for syphilis 5 years ago: sore on his penis, remembers the shot
- 3 female partners in last 6 months, first sexual contact with index patient was 1 month ago
- Denies rashes, ulcers, and none found on exam
- RPR nonreactive
- No drug allergies

Case 4, panel: How would you manage Partner A?

1. Bicillin 2.4MU IM x 1 (and day of treatment RPR)
2. No treatment
3. Repeat RPR in one month

Case 4: what about partner B?

- 29, cis gender man has sex with men and women
- Last sex with index case was 4 months ago.
- In last year has had 1 male and three female sex partners
- Had a rash on his chest, abdomen around Halloween, 2019, nonitchy, resolved
- RPR 1:8, TPPA reactive.
- Last prior RPR was nonreactive, summer 2019; has never been diagnosed with syphilis
- Asymptomatic, cranial nerve exam normal, no hearing loss, tinnitus, floaters, scotomata, cloudy vision

Case 4, panel: How would you manage Partner B?

1. Bicillin 2.4MU IM x 1
2. Bicillin 2.4MU IM weekly x 3 weeks

Case 4: key points

- Syphilis in pregnancy: penicillin is the only treatment. Desensitize if allergic. Desensitization lasts for the duration of penicillin exposure.
- Condyloma Lata HIGHLY infectious mucocutaneous manifestation of 2° syphilis found in anogenital region.
- “Persons who have had sexual contact within the previous with a person who receives a diagnosis of primary, secondary, or early latent syphilis within 90 days preceding the diagnosis should be treated presumptively for early syphilis even if serologic test results are negative.”* If contact tests positive and last sex w index was > 90 days ago, evaluate and treat based on stage.
- Stage based on symptoms, history of the patient on the day you diagnose them: Partner B likely HAD 2° syphilis 14 months ago but HAS late latent today.

*Workowski, Bolen et al. 2015 Sexually Transmitted Disease Treatment Guidelines. Centers for Disease Control and Prevention

EIA+/RPR-/TPPA-  Most likely a false positive EIA

- Next steps, ask the patient if:
 - They have ever had syphilis in past
 - They have any symptoms concerning for early syphilis
 - Any recent sex partners have been diagnosed with syphilis
- If concerning symptoms or contact to syphilis, TREAT for early syphilis (Bicillin 2.4 mu IM x1)
- If no symptoms or contact, likely false positive. Consider repeat screen in 2-4 weeks if concerned for early infection.

Case 5

- 35 yo cisgender man who has sex with cisgender men and women, presents to urgent care with dysuria and scant clear discharge. Physical exam is normal. Urinalysis is positive for WBCs, no leukocyte esterase. You order 3-site GC/CT screening, a syphilis screen, and treat him for NGU with doxycycline.
- Results come back with the following:
 - Urine CT positive (rest of GC/CT tests are negative)
 - EIA positive, RPR negative, TPPA positive
- What do you do?

Case 5, panel: how would you manage?

1. Bicillin 2.4MU IM x1
2. Bicillin 2.4MU IM weekly x 3 weeks
3. No antibiotics, rescreen in 3 months
4. Take a good history

EIA+/RPR-/TPPA+

- 1) Untreated early syphilis (prior to RPR seroconversion)
- 2) Untreated late syphilis
- 3) Previously treated syphilis

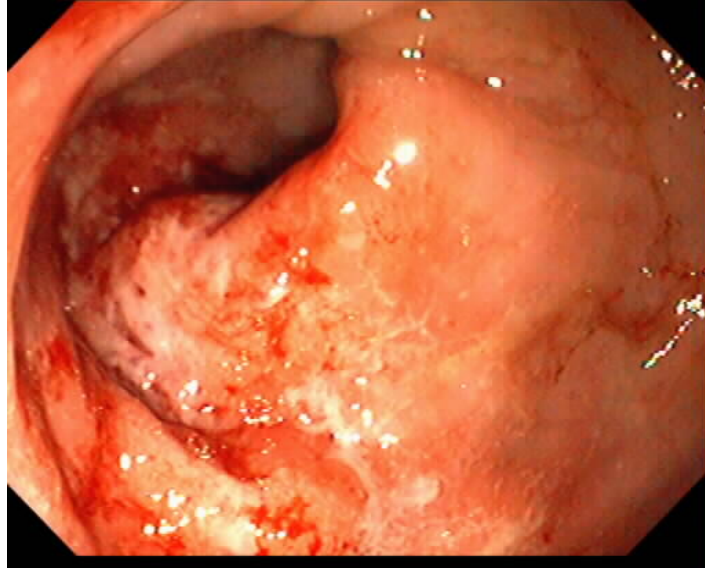
EIA+/RPR-/TPPA+

- History of syphilis, recent symptoms, contact to syphilis?
- Physical exam (mouth, skin, anogenital)
- Call SFCC if you want to consult or to confirm syphilis titer and treatment history
 - 415-487-5595
 - Email Stephanie (stephanie.cohen@sfdph.org) or Oliver (oliver.bacon@sfdph.org)

Thank you!!!

Extra slides

LGV Proctitis (and other causes of proctitis)

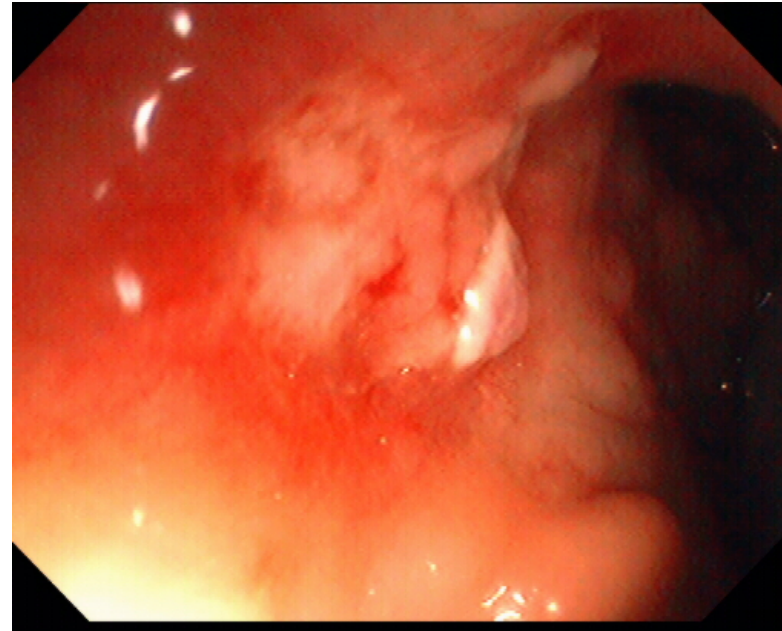


Signs

- *diffuse friability*
- *discrete ulceration*

Symptoms

- *rectal pain*
- *bleeding*



Proctitis Case 2

- Female transgender patient at drop-in HIV primary care clinic. She has chronic rectal discharge and not too much discomfort. CD4 230 c/mm³; HIV RNA <30. On darunavir/cobi/TAF/FTC daily. History of anal condyloma
- Rectal Gram stain unavailable at clinic. Rectal chlamydia and gonorrhea NAATs negative x 2, and syphilis testing is serofast.
- CT scan shows e/o proctitis.
- Panel: what additional testing would you do? Would you treat empirically for *Mycoplasma genitalium*?

Complications

- Incidence of **visual impairment**
 - 0.29/eye year for HIV uninfected
 - 0.21/eye year for HIV infected
- Incidence of **permanent blindness**
 - 0.07/eye year for HIV uninfected
 - 0.06/eye year for HIV infected
- **Risk factors for poor visual outcomes:** longer duration of untreated infection; macular chorioretinitis
- **Long-term complications:** glaucoma, cataract, epiretinal membrane and macular edema, choroidal neovascularization, widespread chorioretinal scarring

